

A CME MONOGRAPH

BLEPHARITIS

2010 Update on Research and Management

A review
of the
literature
and expert
insights

ORIGINAL RELEASE: JULY 15, 2010 | LAST REVIEW: JULY 25, 2010 | EXPIRATION: JULY 30, 2011

Sponsored by **The New York Eye and Ear Infirmary**
Institute for Continuing Medical Education

**NY Eye & Ear
Infirmary**

Continuum Health Partners, Inc.

In joint sponsorship with MedEdicus LLC

MedEdicus

In association with *Ophthalmology Times*

Ophthalmology Times

This continuing medical education activity is supported through
an unrestricted educational grant from Inspire Pharmaceuticals

INSPIRE 

PROGRAM CHAIR AND MODERATOR

Richard L. Lindstrom, MD

PARTICIPANTS

Eric D. Donnenfeld, MD

Gary N. Foulks, MD

Edward J. Holland, MD

Michael A. Lemp, MD

Kelly K. Nichols, OD, MPH, PhD

Terrence P. O'Brien, MD

William B. Trattler, MD

WITH CONTRIBUTIONS BY

Anthony J. Aldave, MD

Elizabeth A. Davis, MD

Marguerite B. McDonald, MD

PROGRAM CHAIR AND MODERATOR

Richard L. Lindstrom, MD

Founder and Attending Surgeon
Minnesota Eye Consultants
Adjunct Professor Emeritus
University of Minnesota,
Department of Ophthalmology
Minneapolis, Minnesota

FACULTY

Anthony J. Aldave, MD

Associate Professor of Ophthalmology
The Jules Stein Eye Institute
The University of California, Los Angeles
Los Angeles, California

Elizabeth A. Davis, MD

Partner
Minnesota Eye Consultants
Adjunct Assistant Clinical Professor
University of Minnesota,
Department of Ophthalmology
Minneapolis, Minnesota

Eric D. Donnenfeld, MD, FAO

Founding Partner
Ophthalmic Consultants of Long Island
Rockville Centre, New York
Clinical Professor of Ophthalmology
NYU Langone Medical Center
New York, New York
Trustee
Dartmouth Medical School
Hanover, New Hampshire

Gary N. Foulks, MD

Arthur and Virginia Keeney Professor
of Ophthalmology
Department of Ophthalmology
and Visual Science
University of Louisville School of Medicine
Louisville, Kentucky

Edward J. Holland, MD

Director, Cornea Services
Cincinnati Eye Institute
Professor of Ophthalmology
The University of Cincinnati
Cincinnati, Ohio

Michael A. Lemp, MD

Clinical Professor of Ophthalmology
Georgetown University School of Medicine
The George Washington University School of Medicine
Washington, DC

Marguerite B. McDonald, MD, FACS

Clinical Professor of Ophthalmology
NYU Langone Medical Center
New York, New York
Adjunct Clinical Professor of Ophthalmology
Tulane University School of Medicine
New Orleans, Louisiana
Ophthalmic Consultants of Long Island
Lynbrook, New York

Kelly K. Nichols, OD, MPH, PhD

Associate Professor
The Ohio State University
College of Optometry
Columbus, Ohio

Terrence P. O'Brien, MD

Professor of Ophthalmology
Charlotte Breyer Rodgers
Distinguished Chair in Ophthalmology
Director of the Refractive Surgery Service
Bascom Palmer Eye Institute
Ocular Microbiology Laboratory
University of Miami
Miller School of Medicine
Palm Beach Gardens, Florida

William B. Trattler, MD

Director of Cornea
Center for Excellence in Eye Care
Volunteer Assistant Professor
of Ophthalmology
Bascom Palmer Eye Institute
University of Miami
Miami, Florida

LEARNING METHOD AND MEDIUM

This educational activity consists of a supplement and ten (10) study questions. The participant should, in order, read the learning objectives contained at the beginning of this supplement, read the supplement, answer all questions in the post test, and complete the evaluation form. To receive credit for this activity, please follow the instructions provided on the post test and evaluation form. This educational activity should take a maximum of 2 hours to complete.

CONTENT SOURCE

This continuing medical education (CME) activity captures content from a CME roundtable discussion held on Thursday, April 8, 2010, prior to the American Society of Cataract and Refractive Surgery Meeting in Boston, Massachusetts.

TARGET AUDIENCE

This educational activity is intended for comprehensive ophthalmologists.

OVERVIEW

Blepharitis negatively affects appearance, comfort, visual function, and surgical outcomes. It is a major cause of evaporative dry eye disease and contact lens intolerance. Despite having first been recognized in the 19th century, blepharitis remains a somewhat poorly defined and understood condition. Recent prevalence and incidence studies have begun to expand our knowledge about the magnitude of the condition. It often coexists with other related conditions, thus complicating its diagnosis and treatment. Blepharitis can be controlled, but not cured, and there remains a lack of a widespread consensus on its management. This activity will provide an update on the current and emerging data, as well as expert insight, on blepharitis prevalence, diagnosis, disease burden, pathophysiology, treatment goals, and treatment options.

LEARNING OBJECTIVES

After successfully completing this activity, you will have improved your ability to:

1. Describe the prevalence of blepharitis
2. Review the pathophysiology of blepharitis
3. Distinguish blepharitis from other ocular conditions
4. Discuss treatment options for blepharitis
5. Develop effective management strategies for blepharitis

ACCREDITATION STATEMENT

This activity has been planned and implemented in accordance with the Essential Areas and Policies of the Accreditation Council for Continuing Medical Education through the joint sponsorship of The New York Eye and Ear Infirmary and MedEdicus LLC. The New York Eye and Ear Infirmary is accredited by the ACCME to provide continuing medical education for physicians.

DESIGNATION STATEMENT

The New York Eye and Ear Infirmary designates this educational activity for a maximum of 2.0 AMA PRA Category 1 Credits™. Physicians should only claim credit commensurate with the extent of their participation in the activity.

MISSION STATEMENT

It is The New York Eye and Ear Infirmary Institute for Continuing Medical Education's stated mission to create medical education activities that will serve to increase the knowledge, skills, professional performance, and relationships that a physician uses to provide services for patients, the public, or the chosen profession.

DISCLOSURE POLICY STATEMENT

The New York Eye and Ear Infirmary requires that each teacher/contributor or individual in a position to control the content of a CME activity accredited by The New York Eye and Ear Infirmary disclose the existence of any relevant financial interests or other relationships (eg, paid speaker, employee, paid consultant on a board and/or committee for a commercial company) that would potentially affect the objectivity of activity content. Teachers/Contributors are also asked to make a disclosure that a product is still investigational when an unlabeled use of a commercial product or an investigational use, not yet approved for any purpose, is discussed during an educational activity. The disclosed information in no way presumes to assess the contributor's qualifications or suitability. The intention is to provide full disclosure of any potential conflict of interest, real or apparent, that is related to a specific educational activity. Individuals who neglect to provide information about relevant financial relationships will be disqualified from serving as a planning committee member, teacher, speaker, moderator, or author of the educational activity. In addition, such individuals will be prohibited from having control of, or the responsibility for, the development, management, presentation, or evaluation of the CME activity. Full disclosure of faculty and commercial relationships, if any, follows.

DISCLOSURES

Anthony J. Aldave, MD: Dr. Aldave had a financial agreement or affiliation during the past year with the following commercial interests in the form of *Consultant/Advisory Board*: Allergan, Inc, and Inspire Pharmaceuticals. *Speakers Bureau*: Alcon, Inc, and Inspire Pharmaceuticals.

Elizabeth A. Davis, MD: Dr. Davis had a financial agreement or affiliation during the past year with the following commercial interests in the form of *Consultant/Advisory Board*: Abbott Medical Optics, Bausch & Lomb Incorporated, Inspire Pharmaceuticals, and ISTA Pharmaceuticals, Inc. *Ownership Interest*: Refractec, Inc. *Speakers Bureau*: Allergan, Inc.

Eric D. Donnenfeld, MD: Dr. Donnenfeld had a financial agreement or affiliation during the past year with the following commercial interests in the form of *Salary/Honoraria*: Advanced Vision Research, Inc; Alcon, Inc; Allergan, Inc; Bausch & Lomb Incorporated; and Inspire Pharmaceuticals. *Consultant/Advisory Board*: Advanced Vision Research, Inc; Alcon, Inc; Allergan, Inc; Bausch & Lomb Incorporated; and Inspire Pharmaceuticals.

Gary N. Foulks, MD: Dr. Foulks had a financial agreement or affiliation during the past year with the following commercial interests in the form of *Consultant/Advisory Board*: Alcon, Inc; Bausch & Lomb Incorporated; Inspire Pharmaceuticals; and Pfizer Inc. *Contracted Research*: Alcon, Inc; Inspire Pharmaceuticals; and TearLab Corporation, Inc. *Ownership Interest*: Inspire Pharmaceuticals.

Edward J. Holland, MD: Dr. Holland had a financial agreement or affiliation during the past year with the following commercial interests in the form of *Consultant/Advisory Board*: Abbott Medical Optics; Advanced Vision Research, Inc; Alcon, Inc; Allergan, Inc; Bausch & Lomb Incorporated; Inspire Pharmaceuticals; OCUSOFT, Inc; QLT Phototherapeutics, Inc; Senju Pharmaceutical Co, Ltd; Sirion Therapeutics; and WaveTec Vision Systems, Inc. *Contracted Research*: Abbott Medical Optics; Alcon, Inc; QLT Inc; Sirion Therapeutics, Inc; and WaveTec Vision Systems, Inc. *Lecture Fees*: Alcon, Inc; Allergan, Inc; and Bausch & Lomb Incorporated.

Michael A. Lemp, MD: Dr. Lemp had a financial agreement or affiliation during the past year with the following commercial interests in the form of *Consultant/Advisory Board*: Inspire Pharmaceuticals, and TearLab Corporation, Inc. *Ownership Interest*: Inspire Pharmaceuticals, and TearLab Corporation, Inc.

Richard L. Lindstrom, MD: Dr. Lindstrom had a financial agreement or affiliation during the past year with the following commercial interests in the form of *Consultant/Advisory Board*: Abbott Medical Optics; Alcon, Inc; Bausch & Lomb Incorporated; and Inspire Pharmaceuticals. *Speakers Bureau*: Allergan, Inc.

Marguerite B. McDonald, MD: Dr. McDonald had a financial agreement or affiliation during the past year with the following commercial interests in the form of *Consultant/Advisory Board*: Abbott Medical Optics; Allergan, Inc; Aton Pharma, Inc; Bausch & Lomb Incorporated; FOCUS Laboratories; Inspire Pharmaceuticals; Ocularis Pharma, Inc; and Santen Pharmaceutical Co, Ltd. *Contracted Research*: Pfizer Inc.

Kelly K. Nichols, OD, MPH, PhD: Dr. Nichols had a financial agreement or affiliation during the past year with the following commercial interests in the form of *Consultant/Advisory Board*: Alcon, Inc; Allergan, Inc; Inspire Pharmaceuticals; and Pfizer Inc. *Ownership Interest*: OccuLogix, Inc.

Terrence P. O'Brien, MD: Dr. O'Brien had a financial agreement or affiliation during the past year with the following commercial interests in the form of *Consultant/Advisory Board*: Abbott (AMO/VISX); Alcon, Inc; Allergan, Inc; Bausch & Lomb Incorporated; ISTA Pharmaceuticals, Inc; and Vistakon Pharmaceuticals, Inc.

William B. Trattler, MD: Dr. Trattler had a financial agreement or affiliation during the past year with the following commercial interests in the form of *Salary/Honoraria*: Allergan, Inc, and Inspire Pharmaceuticals. *Consultant/Advisory Board*: Abbott Medical Optics; Allergan, Inc; Aton Pharma, Inc; Inspire Pharmaceuticals; and Sirion Therapeutics, Inc. *Speakers Bureau*: Abbott Medical Optics; Allergan, Inc; and Inspire Pharmaceuticals. *Contracted Research*: Abbott Medical Optics; Allergan, Inc; Bausch & Lomb Incorporated; Inspire Pharmaceuticals; QLT Inc; and Vistakon Pharmaceuticals, LLC. *Ownership Interest*: CXLUSA.

Robert Laskany, MD, Peer Reviewer: Dr. Laskany had a financial agreement or affiliation during the past year with the following commercial interests in the form of *Royalties*: Sonomed, Inc. *Speakers Bureau*: Alcon, Inc, and Allergan, Inc. *Contracted Research*: ISTA Pharmaceuticals, Inc; Sirion Therapeutics, Inc; and Rapid Pathogen Screening.

EDITORIAL SUPPORT DISCLOSURES

Derek Dore, PharmD, and Cynthia Tornallyay, RD, have no relevant commercial relationships to disclose.

DISCLOSURE ATTESTATION

The contributing physicians listed above have attested to the following: 1. that the relationships/affiliations noted will not bias or otherwise influence their involvement in this activity; 2. that practice recommendations given relevant to the companies with which they have relationships/affiliations will be supported by the best available evidence or, absent evidence, will be consistent with generally accepted medical practice; and 3. that all reasonable clinical alternatives will be discussed when making practice recommendations.

OFF-LABEL DISCUSSION

This activity includes off-label discussion of all the therapies for blepharitis.

GRANTOR STATEMENT

This continuing medical education activity is supported through an unrestricted educational grant from Inspire Pharmaceuticals.

TO OBTAIN CME CREDITS

To obtain CME credit for this activity, read the material in its entirety and consult referenced sources as necessary. Upon successful completion of the post test, your certificate will be issued immediately. Or, you may complete the evaluation form along with the completed post test answer box within this supplement and return via mail to Kim Corbin, Director, ICME, The New York Eye and Ear Infirmary, 310 East 14th Street, New York, NY 10003 or fax to (212) 353-5703. Your certificate will be mailed to the address that you provide on the evaluation form. Please allow 3 weeks for mailed/faxed forms to process. Note: You must score a 70% or higher to receive credit for this activity.

DISCLAIMER

The views and opinions expressed in this educational activity are those of the faculty and do not necessarily represent the views of The New York Eye and Ear Infirmary, MedEdicus, *Ophthalmology Times*, or Inspire Pharmaceuticals. Please refer to the official prescribing information for each product for discussion of approved indications, contraindications, and warnings.

Blepharitis is an inflammatory disease of the lid margin that is common, complex, and has a multifactorial etiology. It is a chronic and progressive condition that can lead to permanent ocular damage. As such, intervening at early stages of disease severity with the use of effective maintenance therapy may improve patient outcomes. However, blepharitis coexists with other common ocular surface conditions and is often underdiagnosed or misdiagnosed and is clearly undertreated, and so we are trying to advance the knowledge in this area for our colleagues so that we can better care for our patients. This CME monograph provides information from published research complemented by practical, clinical insights gathered at a recent roundtable discussion among leading clinicians, educators, and researchers in the specialties of cornea disease management and cataract and refractive surgery.

PREVALENCE AND INCIDENCE OF BLEPHARITIS

THE LITERATURE

In the past, there has been considerable confusion regarding the pathophysiology and, thus, the definition of blepharitis. Because of these uncertainties, an accurate assessment of the prevalence and incidence of the condition has been difficult to achieve. Although blepharitis is one of the most common disorders encountered in eye care practice, limited prevalence or incidence data exist.¹

Hom and colleagues found a pattern of existing, but unrecognized, meibomian gland dysfunction in a sample of randomly selected, apparently normal patients who presented for routine vision examinations. Of 398 patients, 38.9% (155) were found to have meibomian gland dysfunction based on cloudy or absent gland output with repeated expression. Patient profile factors—gender, age, allergies, contact lens wear—were assessed to determine a correlation with meibomian gland dysfunction. Only older age was positively correlated with the prevalence of meibomian gland dysfunction (positive correlation, $P < .0001$).²

Venturino and colleagues reported that chronic blepharitis is the most common condition among patients seeking an eye examination for ocular discomfort or irritation. The 3 most commonly diagnosed clinical conditions were posterior blepharitis 24% (276/1148), dry eye 21% (241/1148), and anterior blepharitis 12% (138/1148). Interestingly, in 54% of cases, treatment was not consistent with the diagnosis at the time of examination, was inappropriate, and led to poorer outcomes in as many as 60% of cases.³

Recently, data from the first large-scale survey of 5000 randomly selected adults in the United States were evaluated to gain better insight into the prevalence of blepharitis symptoms in the general population. Participants were questioned about the

frequency of symptoms associated with lid margin disease over the past 12 months: itching or burning of eyelids; eye irritation after using a computer for more than 3 hours; eyelids feeling heavy or puffy; crust or flakes on eyelashes upon waking; eye dryness or irritation; eyelids sticking together upon waking; eyes feeling watery, especially in the morning; and eye redness upon waking. Of the 5000 individuals, 79.3% reported experiencing at least 1 of the symptoms of lid margin disease within a 12-month period. In addition, 63% reported experiencing more than 1 symptom in the past 12 months (Figure 1). The number of symptoms did not vary by gender; however, men experienced more eyelid crusting/flakes or eye/eyelid redness upon waking, whereas women experienced more eye dryness and irritation, heavy and puffy eyelids, and eye irritation after prolonged computer use. An interesting finding was that symptoms were generally more common in younger individuals, that is, respondents aged 18 to 49 years, compared with those aged 50 years and older. Many of the symptoms characteristic of dry eye were reported by one-third or more of those surveyed. Of the respondents, only 1% had been diagnosed with blepharitis and 11% had been diagnosed with dry eye disease. Overlap of diagnoses was common; of the 1% diagnosed

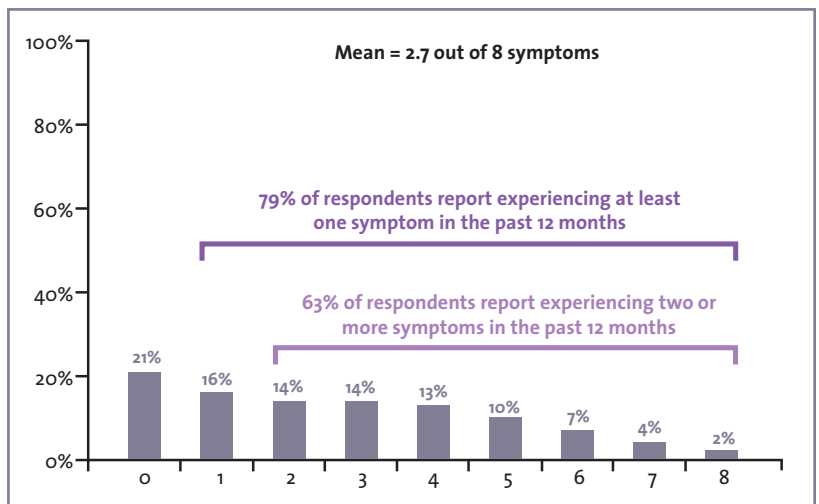


Figure 1. Number of symptoms of lid margin disease experienced in the past 12 months. Reprinted with permission from Lemp MA, Nichols KK. Blepharitis in the United States 2009: a survey-based perspective on prevalence and treatment. *Ocul Surf.* 2009;7(2 suppl):S1-S14.

with blepharitis (50 respondents), 40% also were diagnosed with dry eye disease.¹

To ascertain the frequency with which eye care practitioners encounter the signs and symptoms of blepharitis in clinical practice, 120 ophthalmologists and 84 optometrists were surveyed. Ophthalmologists estimated that 37% of patients who presented to them had some form of blepharitis; optometrists reported that, on average, 47% of the patients they assessed had some form of blepharitis.¹ It is noteworthy to contrast these perceptions with the findings of the previously mentioned survey, that more than 79% of adults exhibit a blepharitis symptom.

Ophthalmologists report that of the patients diagnosed with blepharitis, only 34% sought treatment for blepharitis symptoms, whereas the others initially sought treatment for dry eye symptoms (41%), surgical evaluation (16%), or routine examination/vision complaints (6%). When queried regarding the age and gender of patients most expected to be predisposed to posterior blepharitis/meibomian gland dysfunction, the largest percentage (33%) of ophthalmologists cited men aged older than 65 years, followed by 27% who cited women between the ages of 46 and 65 years. Ninety-six percent of the ophthalmologists agreed or strongly agreed that dry eye disease is a common comorbidity with meibomian gland dysfunction, and 74% agreed or strongly agreed that meibomian gland dysfunction is the most common cause of evaporative dry eye.¹ Similarly, 97% of optometrists agreed or strongly agreed that dry eye disease is a common comorbid condition with posterior blepharitis/meibomian gland dysfunction, and 94% agreed or strongly agreed that posterior blepharitis/meibomian gland dysfunction is the most common cause of evaporative dry eye disease.¹

A large number of patients who are about to undergo ocular surgery have signs and symptoms of blepharitis. It has been estimated that approximately one-third of patients presenting for cataract surgery have blepharitis.⁴ New information from a recent study that found an even higher prevalence⁵ is discussed by William Trattler, MD, in the Clinical Insights section immediately following.

Contact lens wearers are predisposed to ocular conditions. Dry eye is described in approximately 30% to 50% of contact lens wearers. Moreover, contact lens wear is associated with a diminished number of functional meibomian glands—a decrease that is proportional to the duration of contact lens wear. A cross-sectional observational case series found meibomian gland loss of contact lens wearers (mean age \pm standard deviation, 31.8 \pm 8.0 years) to be similar to that of 60- to 69-year-olds from the normal population.⁶ Ong and Larke reported that 30% of contact lens wearers develop some degree of meibomian gland dysfunction following 6 months of wear, in contrast to only 20% of non-lens wearers.⁷

Dr Lemp: *Blepharitis is associated with aging, and one speculation has been that as people age, their expectations change—expectations for excellent health and for feeling good at every part of their body decline and, therefore, they expect discomfort, including ocular discomfort. Thus, they do not report it.*

Dr Trattler: *We recognize that blepharitis incidence is a common situation in patients undergoing cataract surgery. If cataract surgery candidates have blepharitis, the condition may affect their visual results and also perhaps increase the risk of endophthalmitis.*

With colleagues Jodi Luchs, MD, and Carlos Buznego, MD, I conducted a prospective, multicenter observational study to determine the prevalence of blepharitis in patients preparing to undergo routine cataract surgery. Patients were assessed prior to the date of surgery. Procedures included patient-rated assessments of symptoms of blepharitis, investigator-rated signs of blepharitis, biomicroscopy, fluorescein tear film break-up time (TBUT), and fluorescein corneal staining.

The overall prevalence rate of blepharitis was high, 59 out of 100 patients (59%).⁵ On average, patients' signs and symptoms of blepharitis were mild to moderate—overall clinical sign and symptom scores were low, averaging approximately 2 on a scale of 0–4. TBUT, however, was found to be below the normal range: a statistically significant greater number of patients with blepharitis had a TBUT of 5 seconds or less.

We concluded that blepharitis is frequently overlooked in a cataract surgery patient population, possibly because patients with mild symptoms may not complain, and mild clinical signs may be overlooked by the clinician. Yet, despite the absence of signs and symptoms, there may be a real disturbance to the tear film in patients with blepharitis.⁵

Dr Donnenfeld: *We are experiencing an epidemic of meibomian gland dysfunction. This may be becoming a public health issue caused by baby boomers entering old age and by dietary habits having changed dramatically over the past 40 years. Dietary intake has changed from anti-inflammatory, omega-3 fatty acids to pro-inflammatory, omega-6 fatty acids. These changes in dietary habit have contributed to changes in meibomian gland secretions.⁸ In fact, omega-3 fatty acid consumption appears to decrease inflammatory cytokines and improve tear break-up.⁹*

Dr Lindstrom: *There are approximately 45 million people in the United States wearing contact lenses and 120 million in the world—do contact lenses make blepharitis worse?*

Dr Nichols: *With contact lens wear and blepharitis, it is a chicken-and-egg argument. I do believe that the long-term prevalence and incidence of blepharitis is high in this group.*

Approximately 25%, if not more, of patients drop out of contact lens wear, the primary reason being discomfort and dryness. In most of those patients, their lids are not evaluated before they start wearing contact lenses. So, there is an increased need for education—to look at the lids before fitting a contact lens. Also, it could be that the lens, either mechanically or related to all the solutions that patients use, creates some irritation at the lid margin. There are no studies that have assessed long-term contact lens wear and incidence of blepharitis. However, there is evidence that has shown that contact lens wearers have gland loss.⁶ The end result is that patients drop out of contact lens wear; it is possible many of those cases are due to meibomian gland problems.

UNDERDIAGNOSIS AND MISDIAGNOSIS OF BLEPHARITIS

THE LITERATURE

Blepharitis is frequently underdiagnosed in clinical practice.¹ Patients present with a wide array of signs and symptoms, and often signs alone.⁹ Blepharitis is a chronic condition that fluctuates in severity, with patients experiencing periods of exacerbations and remissions.¹⁰ In addition, eye care clinicians increasingly concentrate on the ocular surface, placing less emphasis on the lids. If the blepharitis is asymptomatic, the condition may be easy to overlook.¹ Likewise, blepharitis is often misdiagnosed because of comorbidity with other ocular surface diseases and overlap in the signs and symptoms of evaporative dry eye. Indeed, keratoconjunctivitis sicca has been reported in 50% of patients with staphylococcal blepharitis.^{10,11} Also, blepharitis can coexist with and present as various dermatologic conditions, including rosacea, eczema, and seborrheic dermatitis.¹⁹

UNDERDIAGNOSIS AND MISDIAGNOSIS OF BLEPHARITIS

CLINICAL INSIGHTS

Dr Holland: *It's important to look carefully at the eyelids and conjunctiva in all patients. I do not think clinicians look adequately at the lids as part of the routine examination; there is a tendency to put the slit lamp on high magnification, look right at the cornea and the anterior chamber. Routine careful examination of the anterior and posterior lid, as well as of the conjunctiva, is an important part of a complete evaluation.*

Dr Nichols: *Optometrists are seeing blepharitis with the same frequency as are ophthalmologists, and all eye care providers tend to overlook the condition, especially in the asymptomatic or less severe cases. It has become so commonplace in practice and we need to take more care in recording findings of the lids.*

Dr Lemp: *The underlying cause of dry eye disease in many of our patients may very well be meibomian gland dysfunction.*

Dr Donnenfeld: *In patients who do not respond to treatment for aqueous deficiency dry eye, I suggest clinicians rethink the*

diagnosis and consider that meibomian gland dysfunction is probably the etiology of the patient's symptomatology.

Dr Lindstrom: *So if you are a practicing ophthalmologist or optometrist, and you are not recording blepharitis in 25% to 30% of your routine patient visits and in 60% to 70% of your cataract patients, then I suggest perhaps you are not looking carefully enough.*

PATHOPHYSIOLOGY OF BLEPHARITIS

CLINICAL INSIGHTS

Dr Foulks: *Blepharitis is a general designation for inflammation of the eyelid. Broadly, this includes cutaneous disorders and infectious diseases affecting the skin of the eyelid and the eyelashes. More common clinical use of the term blepharitis refers to lid margin disease. Classically, lid margin disease has been categorized as either the anterior form, which includes the pilosebaceous units of the lid, the eyelashes, and the associated glands, or as the posterior form, which involves the meibomian glands. The pathophysiology differs somewhat for the 2 forms. Posterior lid margin disease, involving the meibomian glands, can result from an abnormality of the meibomian gland, either its anatomy or its secretion, but it is not necessarily associated with much inflammation. It is generally what has been referred to as meibomian gland dysfunction. You have kind of a tripartite decision to make. Is this lid margin disease? Is it anterior or posterior? Does it have inflammation associated with meibomian gland disease or not?*

The pathophysiology of the anterior lid margin is predominantly associated with either bacterial or dermatologic problems, and the role of parasites such as Demodex folliculorum has recently come into question. Demodex infestation has been linked to blepharitis. The mites harbor in eyelashes with cylindrical dandruff.⁹ So, predominantly with anterior blepharitis, we are dealing with either infection or infestation.

With posterior lid margin disease, bacteria produce enzymes that can alter the meibomian gland secretion. The mechanism by which the meibomian gland initiates dysfunction can occur in 3 main areas. One is lack of production of the secretion, or "gland dropout"; another is obstructive disease, which is the much more common of the forms; and lastly, hypersecretory disease, which probably is associated more with dermatologic problems such as rosacea. Obstruction of the meibomian gland can occur by hyperproliferation of epithelium at the orifice of the gland; it can be associated with hyperkeratinization; and, the gland can be obstructed by alteration of the meibomian gland secretion referred to as meibum.

Meibum is a very complex secretion consisting of many different lipids, predominantly cholesterol esters, wax esters,

and triglycerides. When we are younger, meibum is generally an easily free-flowing secretion. As we get older, it tends to change in its fluidity. When there is frank meibomian gland dysfunction, there are changes that occur in the chemistry and physical properties of the secretion, causing the secretion to have a higher melting point. This will lead to stodgy plugged glands (Figure 2; Figure 3). In meibomian gland dysfunction, examination of the meibum will reveal differences in the structure of the hydrocarbon chain that makes up the esters. There is fragmentation of those esters into release of free fatty acids and diglycerides that tend to be very inflammatory or very irritating. There is a process then that results in dysfunction of the delivery of an appropriate meibomian secretion to the tear. The tear becomes unstable, and that is when we start to see alterations of the tear osmolarity and TBUT. So this is a complex issue.

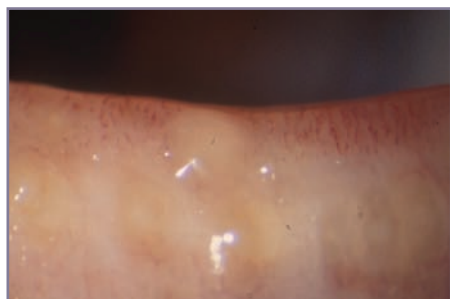


Figure 2. Turbid secretions (G.N. Foulks, MD). Reprinted with permission.

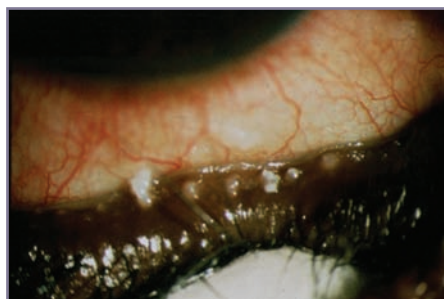


Figure 3. Meibomian gland plugging and capping (G.N. Foulks, MD). Reprinted with permission.

There is inflammation that is stimulated by bacteria, but there is also the innate immune response of the tissues around the meibomian gland that can result in inflammation. As a clinician, you really need to try to determine the variant of the lid margin disease being examined. The same treatment may very well be applied to both forms. You really have to consider, Is there inflammation present? If there is no inflammation present, is the meibomian gland secretion normal or grossly abnormal? Is there obstruction of the orifice of the meibomian gland?

PATHOPHYSIOLOGY OF BLEPHARITIS

THE LITERATURE

Clinically, it is most useful for eye care providers to classify blepharitis as anterior or posterior.¹

Anterior blepharitis affects the anterior portion of the lid margin, including the eyelashes. Both acute and chronic disease is associated with the existence of bacteria on the anterior lid margin, with associated lid margin inflammation. A trio of possible mechanisms underlies anterior blepharitis: 1) direct bacterial infection of the lids; 2) reaction to the presence of endotoxins and/or exotoxins produced by pathogenic bacteria and/or commensal lid flora; 3) cell-mediated delayed hypersensitivity response to bacterial antigens.¹² Bacteria most frequently cultured from blepharitis patients include

Staphylococcus aureus, coagulase-negative *Staphylococcus* spp., *Propionibacterium acnes*, *Staphylococcus epidermidis*, and coryneform bacteria.¹³⁻¹⁵ These pathological mechanisms lead to scaling, crusting, and erythema of the eyelid margin with collarette development at the base of the cilia. The chronic inflammatory state, with episodes of acute exacerbations, can lead to ulcerative blepharitis. In addition, patients may experience madarosis (ie, thinning or loss of lashes) and trichiasis (ie, misdirected lashes). Corneal involvement—punctate epithelial erosions, neovascularization, marginal infiltrates—may occur.^{10,12}

Posterior blepharitis is associated with meibomian gland dysfunction.¹⁶ The primary function of the oily meibum secretions is to delay water evaporation from the surface of the eye.¹⁶ Meibomian gland dysfunction is associated with inflammatory conditions at the lid margins, changes in the anatomy of the gland orifices, and distortion of meibum, which distinguishes it from anterior blepharitis.¹⁶

Meibum is composed of a complex mix of wax esters, cholesterol, cholesterol esters, and phospholipids. The meibum of some individuals contains high levels of cholesterol esters and esters of unsaturated fatty acids. The growth of certain bacteria such as *S aureus* appears to be stimulated by these high levels of cholesterol. Indeed, those with high cholesterol concentrations in their meibum have elevated staphylococcal strains on their lid margins. In turn, esterases and lipases produced by the elevated lid commensal bacteria—*S aureus*, as well as coagulase-negative staphylococci—hydrolyze wax and sterol esters of the meibum, leading to release of fatty acids and monoglycerides and diglycerides into the tear film, creating a soap substance, that is, meibomian foam, that is a source of ocular irritation, tear film instability, and inflammation.^{9,16}

A significant factor in the pathophysiology of posterior blepharitis is thickening of the lipid composition of meibum.¹⁷⁻¹⁹ These changes may have multiple etiologies, such as the presence of a population of certain bacteria, that is, *Staphylococcus* spp. and the lipase enzymes of the bacteria.^{9,18} Hormonal imbalances, such as androgen deficiency, menopause, aging in both genders, and certain autoimmune diseases (eg, Sjögren syndrome) can lead to altered lipid profiles in meibomian gland secretions.^{16,20} A diet with an unfavorably high ratio of omega-6 to omega-3 fatty acids has been implicated in creating a state of inflammation and a change in meibomian gland secretions.⁸

Changes to meibomian gland secretion can lead to varying complications that are commonly observed in patients with

SIGNS TO CONSIDER WHEN EVALUATING A PATIENT FOR THE PRESENCE OF BLEPHARITIS

— Anthony J. Aldave, MD

- 1. FOAMING (SAPONIFICATION) OF TEARS.** Bacterial lipases break down the triglycerides in the meibum to monoglycerides and diglycerides, which are pro-inflammatory. By breaking down the meibum, the bacterial lipases also produce a tell-tale sign of blepharitis, namely saponification of the tear film, often seen best on the lower eyelid margin.
- 2. TRICHIASIS, MADAROSIS, AND TYLOSIS.** Chronic anterior blepharitis will not uncommonly result in structural changes in the eyelash follicle, resulting in misdirected eyelashes (trichiasis), loss of eyelashes (madarosis), and scarring with irregularity of the eyelid margin (tylosis). Thus, blepharitis should be considered as a likely diagnosis in any patient who presents with one or more of these eyelid margin abnormalities.
- 3. ABNORMAL MEIBOMIAN GLAND SECRETIONS.** Although most eye care providers do not routinely express meibum to evaluate the quantity and nature of the meibomian gland secretions, to do so can be a very helpful exercise to aid in making a diagnosis of blepharitis and in categorizing its severity. While some practitioners advocate expressing the meibum using 1 cotton tip applicator in front of the eyelid and a second cotton tip behind the eyelid, in many patients all that is required is to push on the eyelid against the globe using digital pressure placed just below the eyelid margin.
- 4. TBUT (TEAR FILM BREAK-UP TIME).** Although this test is an indirect measure of meibomian gland function, as opposed to the aforementioned assessments of the appearance of the eyelid margin and secreted meibum, TBUT is a very reliable indicator of whether posterior blepharitis may be clinically significant in an individual patient. A decreased TBUT in a patient with symptoms consistent with tear film instability indicates that treatment for the blepharitis is warranted.

SYMPTOMS AND SIGNS TO CONSIDER WHEN EVALUATING A PATIENT FOR THE PRESENCE OF BLEPHARITIS

(aka “the 15-second history and exam for blepharitis”)

— Marguerite B. McDonald, MD

- 1. THE HISTORY:** For patients who express any degree of ocular discomfort, ask them what time of day their eyes look and feel their worst. If the patient feels worst in the morning (usually complaining of some degree of 1 or more of the following symptoms: red, crusty, somewhat itchy, puffy lids and/or red eyes), then the cause of the discomfort is usually blepharitis. If the patient feels worst at night, then the cause is usually dry eye. If the patient is worst in the morning and evening, and less symptomatic during the middle of the day, the diagnosis is usually blepharitis and dry eye—a common combination.
- 2. Apply fluorescein and examine the patient under the slit lamp.** Look for 1 or more of the following: thickened lids; lid margin neovascularization; madarosis, trichiasis, tylosis, or other lash abnormalities; collarettes around the lashes (indicative of anterior blepharitis); and/or foamy tears.
- 3. Two quick maneuvers form the last step:**
 - a. Hold the lids open and observe the TBUT** (less than 10 seconds is clearly abnormal)
 - b. Place the index finger in the center of the lower lid just below the lash line, and push gently.** If a small amount of clear meibum emerges, this is normal; if turbid material emerges, or no material emerges (due to scarring), this is indicative of meibomian gland disease.

blepharitis. The thickened lipids of the meibum, which have a higher melting point, will lead to ductal plugging, stagnation, and pouting of the meibomian gland orifices. These changes contribute to obstructive meibomian gland dysfunction.⁹ The distorted meibomian gland secretions may result in a reduced delivery of meibum to the ocular surface, leading to an unstable tear film and dry eye disease.¹² Once the pathology of posterior blepharitis is initiated, the interaction of abnormal secretions, bacterial products, and inflammatory processes perpetuates and intensifies the pathophysiology of the disease.⁹ Taken together, the pathological mechanisms of posterior blepharitis can lead to burning, irritation, crusting/matter, redness, foreign body sensation, chalazia, tearing; hyperemia, thickening, and irregularity of the lid margins; bulbar conjunctival injection and papillary hypertrophy of the conjunctiva; changes in meibomian gland secretions, meibomian gland obstruction, aqueous tear deficiency, and excess lipid secretion.^{1,12}

RATIONALE FOR TREATMENT

THE LITERATURE

Blepharitis, if not recognized and appropriately managed, can lead to worsening of signs and symptoms^{21,22}; disrupted precorneal tear film,²³ discomfort, changes in visual function, and a negative effect on patient quality of life.²²

Blepharitis is a common cause of contact lens wear intolerance and subsequent discontinuation.²³

For ocular surgery candidates, early and effective treatment of blepharitis can improve outcomes and prevent complications, including endophthalmitis.^{4,24-27}

Perhaps one of the more compelling arguments in favor of treating blepharitis—even in mildly symptomatic or asymptomatic patients—is the prevention of irreversible damage to the meibomian glands. Chronic inflammation within the meibomian glands may lead to changes in gland structure that may permanently disable the function of the gland.²²

TREATMENT GOALS

THE LITERATURE

Blepharitis is a chronic condition that has natural fluctuations of exacerbation and remission.¹⁰ Thus, one of the most important treatment goals is to educate the patient regarding the chronic and recurrent nature of the disease process as well as to ensure that the patient understands that although symptoms can frequently be improved, disease elimination is rarely achieved.¹⁰ Targeting the important pathologic factors—bacteria, inflammation, and meibomian gland dysfunction—is critical to the successful management of blepharitis.¹

Dr Lindstrom: When we treat blepharitis in our patients, they look better, their lid margins are less red, and they do not lose their lashes.

Dr McDonald: With adequate diagnosis and treatment, our patients with blepharitis will enjoy an improvement in their appearance; more comfortable and better vision; increased success with contact lens wear, with less chance of a corneal infection; and an enhanced chance of a successful and rapid recovery from anterior segment surgery, including laser vision correction and phacoemulsification.

Dr O'Brien: I think the issues with treatment of blepharitis are similar to those with the dry eye patient whom we perhaps underdiagnosed and undertreated in the past, but with whom we are now more aggressive. The same is true of the patient with meibomian gland dysfunction. We have underestimated the chronicity, progression, and effect of the inflammatory condition on the ocular surface and on the patient's overall quality of life. If we improve meibomian gland structure and function with our treatment by being more aggressive, the overall effect on vision and quality of life will be greater.

Dr Donnenfeld: I think there is a new paradigm emerging. Most baby boomers entering the senior-citizen age group today have higher expectations than did their parents. They expect to maintain the same level of function and to continue to do the things they did as younger adults. I believe blepharitis and, in particular, meibomian gland dysfunction are affecting baby boomers' quality of life. They are demanding treatment for this disease because it really changes the way they go about their daily activities.

Dr Foulks: Preventing long-term chronic inflammation of the meibomian glands in the posterior lid is important to prevent scarring and vascularization. The vascularization is one of the first things observed, as well as the abnormal character of that vascularization; but then, later, one can see dragging and scarring of the orifices of the meibomian gland with usually posterior traction of those openings, notching of the lid where there has been damage and cicatrization of the tissues around the tarsus.

Dr Holland: When patients advance to that stage, they become much more refractory to treatment. This progression to the advanced stage and the poor prognosis associated with treatment at this stage is why it is important for clinicians to recognize the signs and symptoms of blepharitis early on and to initiate therapy even if the patient is not severely symptomatic.

Dr O'Brien: I completely agree, and find these advanced-stage blepharitis cases similar to end-stage aqueous deficiency cases in which patients experience often less-than-satisfactory response to therapy.

Dr Nichols: Patients who are hedging toward discontinuation of contact lens wear often experience a loss of comfortable wearing hours. Treating blepharitis and thereby improving the quality of the tear film increases contact lens comfortable wearing hours and improves quality of life.²³

PRESURGICAL CONSIDERATIONS

— Elizabeth A. Davis, MD

When ocular surface disease is left untreated, it can complicate surgical procedures such as laser vision correction and cataract surgery.^{28,29} A poor tear film can lead to erroneous preoperative measurements such as those obtained in keratometry, corneal topography, and wavescan aberrometry. This, in turn, can affect refractive outcomes as well as the ability to determine candidacy for surgery.

There is added risk for infection postoperatively in the presence of blepharitis. The lids are the greatest source of offending organisms, and it is imperative they be sterilized preoperatively.³⁰ Also, the inflammation associated with ocular surface disease can induce dry eye and impair wound healing. Thus, I have found it particularly beneficial to treat ocular surface disease aggressively in the preoperative period.

MY PROTOCOL: Although difficult to know the true benefit of preventing infection, I have yet to have a patient develop endophthalmitis on this regimen since instituting it more than a year ago.

1. I screen all patients carefully for the presence of both blepharitis and dry eye. Neither is an absolute contraindication for surgery, but both must be well controlled.
2. All my cataract surgery patients take azithromycin daily in the operative eye 1 week preoperatively.
3. Postoperatively, antibiosis is achieved with a fourth-generation fluoroquinolone 4 times per day for approximately 2 weeks.

With this regimen, I have been able to reduce the incidence of dry eye signs and symptoms (foreign body sensation, irritation, burning, and itching), obtain a better tear film quantity and quality, along with an enhanced visual outcome.

CURRENT AND FUTURE MANAGEMENT OF BLEPHARITIS

THE LITERATURE

A paradigm shift appears to be occurring in the treatment of blepharitis. Whereas traditionally, warm compress therapy and antibiotic ointment application have been the mainstays of treatment, many eye care clinicians are now using prescription antibiotic therapy as the treatment foundation.¹ The treatment approach involves 2 phases: the acute phase and the maintenance phase. In the acute phase, therapeutic modalities are used to aggressively control the disease process and provide symptomatic relief. The aim of the maintenance phase is to maintain long-term control of the disease with a minimal amount of therapy required.¹²

Currently, there are no US Food and Drug Administration-approved treatments for blepharitis. Heat and lid hygiene provide a nonpharmacological approach to the treatment of blepharitis. Warm compresses and lid scrubs work together to collectively decrease lid margin debris; liquefy stagnant, partially solidified meibomian gland secretions; and decrease bacterial counts. Eyelid hygiene performed once daily is generally effective.¹⁰

Oral omega-3 dietary supplementation (two 1000-mg capsules 3 times a day) for 12 months has been shown to improve tear production and stability (TBUT), Ocular Surface Disease Index score, and meibum score.⁸

The use of oral tetracycline antibiotics in blepharitis is founded on small clinical trials that show their efficacy in improving symptoms of ocular rosacea and improving TBUT in patients with rosacea and meibomian gland dysfunction. Oral tetracyclines decrease *S epidermidis*- and *S aureus*-lipase production, leading to decreased inflammatory activity. Multiple daily doses and side effects are drawbacks of the tetracycline family of antibiotics. The use of sustained-release, lower-dose doxycycline is associated with a lower rate of side effects.¹⁰ Oral macrolide antibiotics—erythromycin and azithromycin—have anti-inflammatory activity. Use of oral erythromycin can be limited by a wide array of potential drug interactions.³¹ Oral azithromycin may cause adverse events related to the gastrointestinal tract.³²

Topical administration of antibiotics is favored over systemic administration in the treatment of ocular infections because it provides direct dosing to the target tissue, less systemic toxicity, more rapid onset of action, and minimal dosing requirements compared with oral agents.³³

Traditionally, the topical ophthalmic antibiotic ointments bacitracin and erythromycin were used because of their broad spectrum antimicrobial activity and good tolerability.³⁴ Their popularity has diminished, however, in favor of agents with broader antibacterial activity, anti-inflammatory activity,¹ and better patient outcomes.³⁵

Advanced-generation fluoroquinolones have broad-spectrum anti-infective activity, being effective against gram-positive and gram-negative anaerobic bacteria.³⁶ Topical ciprofloxacin, moxifloxacin, and gatifloxacin are used in the treatment of blepharitis; however, they appear to be the least frequently prescribed treatment among eye care providers,¹ likely because of the concern that long-term use will lead to increasing bacterial resistance.⁹

Azithromycin, a macrolide antibiotic, can treat gram-positive, gram-negative, and atypical infections successfully.³⁷ It has anti-inflammatory activity independent of its antibacterial activity.³⁸ Currently, azithromycin ophthalmic solution, 1% in a bioadhesive ocular drug delivery system is the only treatment option seeking an indication for blepharitis. Two recently completed phase 2 clinical trials evaluated the safety and efficacy of azithromycin in blepharitis-related signs, such as eyelid margin erythema, and symptoms.^{37,39,40} Azithromycin did not meet the primary end points in these trials; the information retrieved, however, will be used to further research the agent in blepharitis.⁴¹ Topical azithromycin, 1% ophthalmic solution has been shown in a recent open-label study to improve the character and behavior of lipids in meibomian gland secretion in a way that correlates with improved signs and symptoms.⁴²

In a study of chronic mixed anterior blepharitis, azithromycin ophthalmic solution was shown to be more effective than erythromycin ophthalmic ointment; 98.5% of azithromycin-treated patients experienced total clinical resolution after 4 weeks compared with 37.5% of erythromycin-treated patients.³⁵ In a study of patients with posterior blepharitis, azithromycin ophthalmic solution in combination with warm compresses provided significantly greater improvements in meibomian gland plugging, meibomian gland secretions, and eyelid redness compared with warm compress use alone.⁴³ Eye irritation, which occurs in approximately 1% to 2% of patients, is the most common ocular adverse reaction.⁴⁴

A short-term course of topical corticosteroids is effective for eyelid and ocular surface inflammation. Monitoring for adverse events, such as increased intraocular pressure and cataract, is important, particularly if long-term use cannot be avoided.^{9,10} Adverse events may be lessened, however, by the use of a site-specific corticosteroid such as loteprednol etabonate and agents with low ocular penetration, such as fluoromethalone.¹⁰

Topical steroid and antibiotic combinations (dexamethasone, 0.1%/tobramycin, 0.3% and loteprednol etabonate, 0.5%/tobramycin, 0.3%) provide the combination of anti-inflammatory and antibacterial action.⁴⁵ Such combinations are not indicated for the treatment of blepharitis, but they have shown efficacy in the treatment of blepharokeratoconjunctivitis and so are used off-label for blepharitis. A recent survey of agents used reported similar preferences by ophthalmologists and optometrists. Azithromycin ophthalmic solution, 1% was preferred most for both blepharitis (in all forms) and posterior blepharitis/meibomian gland

dysfunction patients, followed by oral doxycycline; the anti-inflammatory agents (cyclosporine, loteprednol etabonate, and the combination agent dexamethasone/tobramycin) ranked next, with bacitracin and erythromycin ointments following, and the fluoroquinolones (moxifloxacin, gatifloxacin, and ciprofloxacin) being the last choice.¹ Topical cyclosporine, 0.05% may be effective in select cases of posterior blepharitis because of its anti-inflammatory properties (reducing inflammation in meibomian glands and reducing plugging and dysfunction), although the agent provides inconsistent symptomatic relief.^{46,47}

Artificial tears, when used in a regimen that includes lid hygiene and medications, may be helpful in improving certain symptoms in patients who are aqueous tear deficient.¹⁰ Weekly 50% tea-tree oil with eyelid scrubs and daily tea-tree oil shampoo scrubs appear to improve signs and symptoms associated with blepharitis.¹⁰

CURRENT AND FUTURE MANAGEMENT OF BLEPHARITIS

CLINICAL INSIGHTS

Dr Lindstrom: *As we know, there has been insufficient evidence to make definitive treatment recommendations for blepharitis, but we can expect some guidance in the near future. Dr Nichols, please describe the project on which you are working.*

Dr Nichols: *The International Workshop on Meibomian Gland Dysfunction (sponsored by the Tear Film & Ocular Surface Society) is an evidence-based review of the literature that covers several topical areas including anatomy, physiology, epidemiology, the diagnosis, management, and clinical trials on the meibomian gland in health and disease. Approximately 50 individuals from all over the world have been working on separate reports. This will be the most comprehensive document that exists on meibomian gland dysfunction and will provide insight into future directions for both research and clinical care.*

Dr Lindstrom: *We try to provide therapy that is appropriate to the pathophysiology at hand. Because anterior lid margin disease involves infection or infestation, we are going to treat either bacteria or Demodex. But in posterior segment disease, abnormal lipids and inflammation are the culprits, so an agent with dual activity—antibacterial and anti-inflammatory—might help bring the lipids into a more normal composition.*

Dr O'Brien: *As a result of new understanding of the pathophysiology of blepharitis, we may be considering a third area of treatment efficacy beyond the antimicrobial and anti-inflammatory effects, and that is the favorable alteration of the physicochemical properties of meibum. Now whether it is a combination of the antimicrobial and anti-inflammatory therapies that leads to the physicochemical change, or some independent, direct action of the treatment on the meibum secretions, bringing about such physicochemical change may lead to clinically beneficial effects, such as improvement in stability of the tear film, visual function, and even patient quality of life.*

Dr Lindstrom: What is the best treatment approach?

Dr O'Brien: Blepharitis is chronic and it is progressive. We want to intervene at earlier stages of severity to prevent some of the irreversible cicatricial changes. Thus, as clinicians, we should focus on early diagnosis, stratification and classification, and then application of a broad-based, multifaceted treatment approach to alleviate symptoms and signs.

Dr Donnenfeld: Education is the place to start. Patients have to understand why you are treating them and why the treatment is important.

Dr O'Brien: One of the mainstays of treatment has been lid hygiene and localized hyperthermia, but over the years, it has been difficult to define exactly how to do that and for what period of time, and what level of temperature for compresses is essential.

Dr Trattler: Patients often have difficulty being able to spend 10 minutes each day for lid hygiene versus using an eye drop that can be administered just once a day. So I have moved away from lid hygiene for my patients.

Dr Foulks: I also ask my patients about diet and use of omega-3 fatty acids.

Dr Lemp: To achieve a therapeutic effect, 3 grams of omega-3 intake is needed per day.⁸

Dr Lindstrom: In addition to recommending lid hygiene, hyperthermia, and the nutritional supplements to improve the quality of their lipids, we provide our patients a topical antibiotic with anti-inflammatory effects to treat the inflammation and kill the bacteria in the lids that are causing this disease. The classic antibiotic we used was erythromycin, but it did not seem to have the desired anti-inflammatory effect.³⁵ And most of us feel that for chronic long-term low-dose therapy, a fluoroquinolone is inappropriate, because we do not want to create resistant organisms.⁹

Dr Donnenfeld: Until recently, we did not have an antibiotic that was applied topically that had the dual activity of providing an antibacterial effect and an anti-inflammatory effect—and one that also was able to penetrate into the meibomian gland orifices. The availability of topical azithromycin has helped the management of meibomian gland dysfunction.

Dr Holland: If a patient is still frustrated with the level of improvement in his or her symptoms and we have not reached the maximum effect of azithromycin treatment, or if there is corneal involvement, I may add a topical steroid such as loteprednol and taper as symptoms improve. There are great benefits in both aqueous tear deficiency and meibomian gland disease achieved with topical steroids.⁴⁸

Dr Donnenfeld: The tear film is composed of lipid, aqueous, and mucin. So many patients have mixed-mechanism disease that the use of long-term azithromycin to improve lipid secretion along with the use of long-term cyclosporine to improve aqueous production and goblet cell function⁴⁹ can have a synergistic effect of improving the quality of the tear film as well as the quality of meibomian gland secretions.

Dr O'Brien: I also want to say a word about topical ocular lubricants, which, for some patients, certainly play a role in the therapeutic regimen. One of the things to be careful of is the preservative-containing lubricants being used excessively; a high amount of preservative can decrease tear film stability and may add insult to the already injured ocular surface. I think it is better to have a prescribed dosage of 3 to 4 times spread out throughout the day.

Dr Trattler: Artificial tears play a role early on, and there are some great options available, for example, preservative-free agents including those with hyaluronic acid that can make a difference for ocular surface conditions.⁵⁰

Dr Holland: Any time you can treat topically and get a beneficial effect, I think you should. But there are patients who do not respond or do not achieve a complete response, or those with acne rosacea and facial involvement. These patients are good candidates for oral antibiotics, such as the oral tetracyclines, preferably in lower-dose preparations, which can have a great effect on patients' tear function without adverse events and multiple daily doses.¹⁰

Dr McDonald: And “the elephant in the corner” is the frequent disconnect between signs and symptoms. In this matter, blepharitis is like glaucoma: many patients have no or very mild symptoms in spite of fairly dramatic disease. A general education campaign for the public will help in this regard, as it is currently difficult to put asymptomatic patients on a treatment regimen.

CONCLUSION

Blepharitis is a common ocular condition with a complex multifactorial etiology. Often, it is not diagnosed in clinical practice because patients may be asymptomatic or present with mild signs and symptoms. The condition can be misdiagnosed because it coexists with other common ocular surface conditions, such as dry eye. Blepharitis is an inflammatory chronic condition associated with bacterial infection and alterations in the meibomian glands. If not recognized and appropriately managed, blepharitis can lead to substantial clinical consequences. Treatment that is effective and addresses the multiple pathogenic factors of blepharitis may enhance patient quality of life, relieve discomfort associated with contact lens wear, improve ocular surgery outcomes, and prevent permanent ocular damage. We look forward to additional information on the etiology and management of blepharitis as consensus reports emerge in the near future.

REFERENCES

- Lemp MA, Nichols KK. Blepharitis in the United States 2009: a survey-based perspective on prevalence and treatment. *Ocul Surf.* 2009;7(2 suppl):S1-S14.
- Hom MM, Martinson JR, Knapp LL, Paugh JR. Prevalence of meibomian gland dysfunction. *Optom Vis Sci.* 1990;67(9):710-712.
- Venturino G, Bricola G, Bagnis A, Traverso CE. Chronic blepharitis: Treatment patterns and prevalence. *Invest Ophthalmol Vis Sci.* 2003;44:E-Abstract 774.
- Lindstrom RL. The effects of blepharitis on ocular surgery. *Ocul Surf.* 2009;7(2 suppl):S19-S20.
- Luchs J, Buznego C, Trattler W. Incidence of blepharitis in patients undergoing phacoemulsification. Poster presented at: American Society of Cataract and Refractive Surgery Symposium and Congress; April 9-14, 2010; Boston, MA.
- Arita R, Itoh K, Inoue K, Kuchiba A, Yamaguchi T, Amano S. Contact lens wear is associated with decrease of meibomian glands. *Ophthalmology.* 2009;116(3):379-384.
- Ong BL, Larke JR. Meibomian gland dysfunction: some clinical, biochemical and physical observations. *Ophthalmic Physiol Opt.* 1990;10(2):144-148.
- Macasai MS. The role of omega-3 dietary supplementation in blepharitis and meibomian gland dysfunction (an AOS thesis). *Trans Am Ophthalmol Soc.* 2008;106:336-356.
- Jackson WB. Blepharitis: current strategies for diagnosis and management. *Can J Ophthalmol.* 2008;43(2):170-179.
- American Academy of Ophthalmology Cornea/External Disease Panel. Preferred Practice Pattern® Guidelines. Blepharitis. San Francisco, CA: American Academy of Ophthalmology; 2008. <http://www.aao.org/ppp>. Accessed May 29, 2010.
- McCulley JP, Dougherty JM, Deneau DG. Classification of chronic blepharitis. *Ophthalmology.* 1982;89(10):1173-1180.
- Smith RE, Flowers CW Jr. Chronic blepharitis: a review. *CLAO J.* 1995;21(3):200-207.
- Dougherty JM, McCulley JP. Comparative bacteriology of chronic blepharitis. *Br J Ophthalmol.* 1984;68(8):524-528.
- Groden LR, Murphy B, Rodniti J, Genvert GI. Lid flora in blepharitis. *Cornea.* 1991;10(1):50-53.
- McCulley JP, Dougherty JM. Bacterial aspects of chronic blepharitis. *Trans Ophthalmol Soc U K.* 1986;105(pt 3):314-318.
- Foulks GN, Bron AJ. Meibomian gland dysfunction: a clinical scheme for description, diagnosis, classification, and grading. *Ocul Surf.* 2003;1(3):107-126.
- Shine WE, McCulley JP. The role of cholesterol in chronic blepharitis. *Invest Ophthalmol Vis Sci.* 1991;32(8):2272-2280.
- Shine WE, Silvany R, McCulley JP. Relation of cholesterol-stimulated Staphylococcus aureus growth to chronic blepharitis. *Invest Ophthalmol Vis Sci.* 1993;34(7):2291-2296.
- Shine WE, McCulley JP. Role of wax ester fatty alcohols in chronic blepharitis. *Invest Ophthalmol Vis Sci.* 1993;34(13):3515-3521.
- Sullivan BD, Evans JE, Krenzer KL, Reza Dana M, Sullivan DA. Impact of antian-drogen treatment on the fatty acid profile of neutral lipids in human meibomian gland secretions. *J Clin Endocrinol Metab.* 2000;85(12):4866-4873.
- American Optometric Association. Blepharitis. <http://www.aoa.org/Blepharitis.xml>. Accessed April 20, 2010.
- McDonald MB. The patient's experience of blepharitis. *Ocul Surf.* 2009;7(2 suppl):S17-S18.
- American Optometric Association. Optometric Clinical Practice Guideline: Care of the patient with ocular surface disorders. 2003. <http://www.aoa.org/Blepharitis.xml>. Accessed April 20, 2010.
- Hardten DR. The cornea in cataract and intraocular lens surgery. *Curr Opin Ophthalmol.* 1997;8(1):33-38.
- Karimian F, Baradaran-Rafii A, Javadi MA, Nazari R, Rabei HM, Jafarinasab MR. Bilateral bacterial keratitis in three patients following photorefractive keratectomy. *J Refract Surg.* 2007;23(3):312-315.
- Ambrosio R Jr, Periman LM, Netto MV, Wilson SE. Bilateral marginal sterile infiltrates and diffuse lamellar keratitis after laser in situ keratomileusis. *J Refract Surg.* 2003;19(2):154-158.
- Bertino JS. Impact of antibiotic resistance in the management of ocular infections: the role of current and future antibiotics. *Clin Ophthalmol.* 2009;3:507-521.
- Toda I. LASIK and the ocular surface. *Cornea.* 2008;27(8)(suppl 1):S70-S76.
- Li XM, Hu L, Hu J, Wang W. Investigation of dry eye disease and analysis of the pathogenic factors in patients after cataract surgery. *Cornea.* 2007;26(9 suppl 1):S16-S20.
- Wu PC, Li M, Chang SJ, et al. Risk of endophthalmitis after cataract surgery using different protocols for povidone-iodine preoperative disinfection. *J Ocul Pharmacol Ther.* 2006;22(1):54-61.
- Erythromycin ethylsuccinate tablet [package insert]. North Chicago, IL: Abbott Laboratories; 2009.
- Amar T, Caillaud T, Elena PP. Ocular pharmacokinetic study following single and multiple azithromycin administrations in pigmented rabbits. *Curr Eye Res.* 2008;33(2):149-158.
- Torkildsen G, O'Brien TP. Conjunctival tissue pharmacokinetic properties of topical azithromycin 1% and moxifloxacin 0.5% ophthalmic solutions: a single-dose, randomized, open-label, active-controlled trial in healthy adult volunteers. *Clin Ther.* 2008;30(11):2005-2014.
- Raskin EM, Speaker MG, Laibson PR. Blepharitis. *Infect Dis Clin North Am.* 1992;6(4):777-787.
- John T, Shah AA. Use of azithromycin ophthalmic solution in the treatment of chronic mixed anterior blepharitis. *Ann Ophthalmol (Skokie).* 2008;40(2):68-74.
- Haas W, Pillar CM, Zurenko GE, Lee JC, Brunner LS, Morris TW. Besifloxacin, a novel fluoroquinolone, has broad-spectrum in vitro activity against aerobic and anaerobic bacteria. *Antimicrob Agents Chemother.* 2009;53(8):3552-3560.
- Friedlaender MH, Protzko E. Clinical development of 1% azithromycin in DuraSite®, a topical azalide anti-infective for ocular surface therapy. *Clin Ophthalmol.* 2007;1(1):3-10.
- Ianaro A, Ialenti A, Maffia P, et al. Anti-inflammatory activity of macrolide antibiotics. *J Pharmacol Exp Ther.* 2000;292(1):156-163.
- ClinicalTrials.gov. The effects of azithromycin ophthalmic solution, 1% versus placebo in subjects with blepharitis during a four-week treatment period. <http://www.clinicaltrials.gov/ctz/show/NCT00894530?term=blepharitis+azasite&rank=5>. Updated March 16, 2010. Accessed April 24, 2010.
- ClinicalTrials.gov. The effects of azithromycin ophthalmic solution, 1% versus placebo in subjects with blepharitis during a two-week treatment period. <http://www.clinicaltrials.gov/ctz/show/NCT00892970?term=blepharitis+azasite&rank=6>. Updated March 16, 2010. Accessed April 24, 2010.
- Inspire Announces Results From AZASITE(R) Phase 2 Blepharitis Trials and Plans to Continue Clinical Development in Anterior and Posterior Blepharitis [press release]. Durham, NC: Inspire Pharmaceuticals, Inc; March 15, 2010. <http://ir.inspirepharm.com/phoenix.zhtml?c=120779&p=irol-newsArticle&ID=1402141&highlight=>. Accessed May 9, 2010.
- Foulks GN, Borchman D, Yappert M, Kim SH, McKay JW. Topical azithromycin therapy for meibomian gland dysfunction: Clinical response and lipid alterations. *Cornea.* 2010 May 20. [Epub ahead of print]
- Luchs J. Efficacy of topical azithromycin ophthalmic solution 1% in the treatment of posterior blepharitis. *Adv Ther.* 2008;25(9):858-870.
- Azasite 1% [package insert]. Durham, NC: Inspire Pharmaceuticals Inc; 2008.
- Comstock TL, Holland EJ. Loteprednol and tobramycin in combination: a review of their impact on current treatment regimens. *Expert Opin Pharmacother.* 2010;11(5):843-852.
- Rubin M, Rao SN. Efficacy of topical cyclosporin 0.05% in the treatment of posterior blepharitis. *J Ocul Pharmacol Ther.* 2006;22(1):47-53.
- Perry HD, Doshi-Carnevale S, Donnerfeld ED, Solomon R, Biser SA, Bloom AH. Efficacy of commercially available topical cyclosporine A 0.05% in the treatment of meibomian gland dysfunction. *Cornea.* 2006;25(2):171-175.
- Pflugfelder SC, Maskin SL, Anderson B, et al. A randomized, double-masked, placebo-controlled, multicenter comparison of loteprednol etabonate ophthalmic suspension, 0.5%, and placebo for treatment of keratoconjunctivitis sicca in patients with delayed tear clearance. *Am J Ophthalmol.* 2004;138(3):444-457.
- Sall K, Stevenson OD, Mundorf TK, Reis BL. Two multicenter, randomized studies of the efficacy and safety of cyclosporine ophthalmic emulsion in moderate to severe dry eye disease. CsA Phase 3 Study Group. *Ophthalmology.* 2000;107(4):631-639.
- Vogel R, Crockett RS, Oden N, Laliberte TW, Molina L; Sodium Hyaluronate Ophthalmic Solution Study Group. Demonstration of efficacy in the treatment of dry eye disease with 0.18% sodium hyaluronate ophthalmic solution (vismed, rejena). *Am J Ophthalmol.* 2010;149(4):594-601.

CME POST TEST

To obtain CME credit for this activity, you must complete the post test by writing the best answer to each question in the **Answer Box** located on the **Activity Evaluation** form.

- In the telephone interview survey of 5000 randomly selected adults in the United States, approximately what percentage reported experiencing at least 1 of the symptoms of lid margin disease within a 12-month period?
 - 30%
 - 50%
 - 60%
 - 80%
 - 100%
- In a survey of 120 ophthalmologists, ___ agreed or strongly agreed that dry eye disease is a common comorbidity with meibomian gland dysfunction.
 - 26%
 - 46%
 - 76%
 - 96%
 - None of the above
- Which of the following may lead to the underdiagnosis or misdiagnosis of blepharitis?
 - Asymptomatic blepharitis
 - Blepharitis presenting as a comorbid condition with other ocular surface diseases, such as evaporative dry eye, which has similar signs and symptoms
 - Blepharitis presenting in concert with dermatologic conditions, such as rosacea, eczema, and seborrheic dermatitis
 - A and C
 - All the above
- Signs and symptoms of blepharitis may be caused by:
 - Bacterial products
 - Inflammation
 - Altered meibomian gland secretions
 - Meibomian gland dysfunction
 - All the above
- Blepharitis of the anterior lids and lashes may be caused by:
 - Direct bacterial infection of the lids
 - Reaction to viral exotoxins
 - Excess sun exposure
 - Tinea capitis infection
 - All the above
- Which of the following factors may directly or indirectly contribute to the pathophysiology of posterior blepharitis?
 - Obstructive pituitary gland dysfunction
 - Altered meibomian gland secretions
 - Thyroid hormone deficiency
 - Lid commensal viral lipases
 - All the above
- Which of the following may be prevented by treating blepharitis?
 - Worsening of signs and symptoms
 - Poor ocular surgery outcomes
 - Irreversible ocular damage
 - All the above
 - None of the above
- Which of the following is/are true regarding the management of blepharitis?
 - Patients should be educated that blepharitis is a chronic, recurrent disease and that although symptoms can be frequently improved, disease elimination is rarely achieved
 - A large amount of data supports the use of oral tetracyclines in the treatment of blepharitis
 - Omega-3 fatty acids may decrease inflammatory cytokines and improve tear break-up time
 - The long-term use of topical corticosteroids is recommended for the treatment of mild blepharitis
 - A and C
- Which of the following is true for nonpharmacologic management of blepharitis?
 - Strong scientific evidence supports specific protocols for eyelid hygiene and heat therapy
 - Eyelid hygiene performed once daily is generally effective
 - Patient compliance with heat and lid hygiene therapy is nearly 100%
 - A and B are true
 - All the above are true
- Which of the following is true regarding the efficacy of agents in the treatment of blepharitis?
 - Topical cyclosporine, 0.05% may be effective in some cases of posterior blepharitis
 - A short-term course of topical corticosteroids is effective for eyelid and ocular surface inflammation
 - Artificial tears, in combination with lid hygiene and medications, can improve certain symptoms in aqueous tear deficient patients
 - Azithromycin ophthalmic solution, 1% has been shown to be more effective than erythromycin in anterior blepharitis; and in combination with warm compresses, it has been shown to be more effective than warm compresses alone in posterior blepharitis
 - All the above are true

ACTIVITY EVALUATION

BLEPHARITIS 2010

Update on Research
and Management

ORIGINAL RELEASE: JULY 15, 2010 | LAST REVIEW: JULY 25, 2010 | EXPIRATION: JULY 30, 2011

To receive CME credit, please complete this evaluation form and mail or fax it to The New York Eye and Ear Infirmary-ICME, 310 East 14th Street, New York, NY 10003 (Fax: 212-353-5703). You must complete the post test by recording the best answer to each question in the answer key located below. Your comments help us to determine the extent to which this educational activity has met its stated objectives, assess future educational needs, and create timely and pertinent future activities. Please provide all the requested information below. This ensures that your certificate is filled out correctly and is mailed to the proper address. It also enables us to contact you about future CME activities. Please print clearly or type. Illegible submissions cannot be processed.

PARTICIPANT INFORMATION (Please Print) Home Office

Last Name _____

First Name _____

Specialty _____ Degree: MD DO PharmD RPh NP RN PA Other

Institution _____

Street Address _____

City _____ State _____ ZIP Code _____ Country _____

Phone _____ Fax _____

E-Mail _____

PLEASE NOTE: We do not sell or share e-mail addresses. They are used strictly for conducting post-activity follow-up surveys that are required by the Accreditation Council for Continuing Medical Education (ACCME).

LEARNER DISCLOSURE: To ensure compliance with the U.S. Centers for Medicare and Medicaid Management Stark Law regarding gifts to physicians, the New York Eye & Ear Infirmary Institute for CME requires that you disclose whether or not you have any financial, referral and/or other relationship with our institution. CME certificates cannot be awarded unless you answer this question. For additional information, please call the NYEE ICME at 212-979-4383. Thank you.

Yes No I and/or my family member have a financial relationship with the NY Eye & Ear Infirmary and/or refer Medicare/Medicaid patients to it.

I certify that I have participated in the entire activity and claim 2 credits.

Signature Required _____ Date Completed _____

Yes No Did you perceive any commercial bias in any part of this activity? If yes, please specify content and/or contributor.

Circle the number that best reflects your opinion on the degree to which the following learning objectives were met:

ACTIVITY RATING: 5 = STRONGLY AGREE 4 = AGREE 3 = NEUTRAL 2 = DISAGREE 1 = STRONGLY DISAGREE

After successfully completing this activity, I have improved my ability to:

1. Describe the prevalence of blepharitis	5	4	3	2	1
2. Review the pathophysiology of blepharitis	5	4	3	2	1
3. Distinguish blepharitis from other ocular conditions	5	4	3	2	1
4. Discuss treatment options for blepharitis	5	4	3	2	1
5. Develop effective management strategies for blepharitis	5	4	3	2	1

EDUCATIONAL OBJECTIVES

1. Please list one or more things you learned from participating in this educational activity that you did not already know.

2. As a result of this activity, I plan to make the following changes in my practice:

3. Please check the Core Competencies (as defined by the Accreditation Council for Graduate Medical Education) that were enhanced for you through participation in this activity. Patient Care Practice-Based Learning and Improvement Professionalism
 Medical Knowledge Interpersonal and Communication Skills Systems-Based Practice

4. What barriers to patient care do you face?

What other educational topics would you like to have in future CME programs?

POST TEST ANSWER BOX

1	2	3	4	5	6	7	8	9	10

